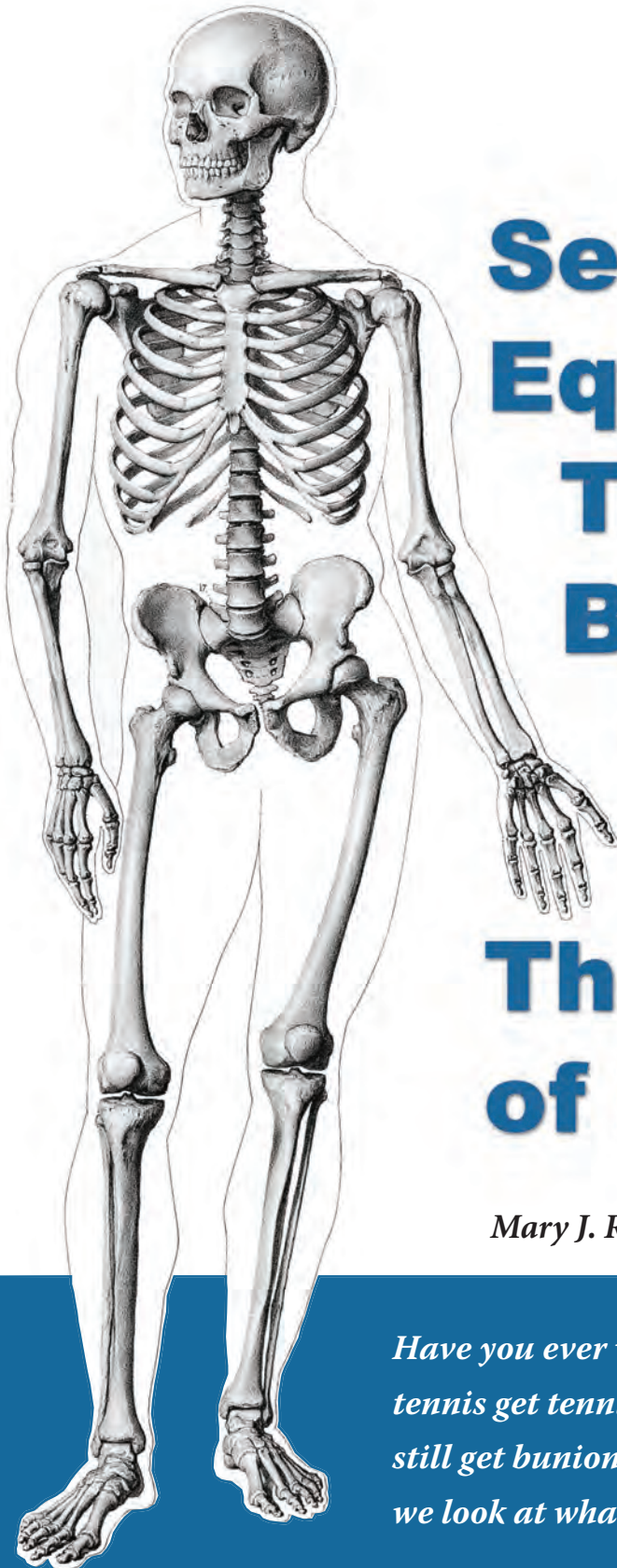


This article is based on a radio show entitled  
"Keys to the Kingdom" that aired on VoiceAmerica internet radio on April 30, 2014.



# Seeking Equilibrium: The Dynamic Body and the Keys to the Kingdom: The Anatomy of Holism

*Mary J. Rogel, PhD, LAc*

*Have you ever wondered why people who do not play tennis get tennis elbow, or why people who wear good shoes still get bunions? The reasons are not so mysterious when we look at what ligaments do for us.*

## The Power of Language

The language we use to talk about what is wrong with us is very, very powerful. The words we use give us expectations about outcomes and consequences. For example, thinking about the body as though it is a machine gives us the idea that parts are replaceable. When a part wears out, we expect that we can replace it. That is how medicine today has come to focus on joint replacements and organ transplants. It is our concept of the body as a machine that has allowed us to develop a medicine that is focused on replacing body parts because the language we use affects the way we think.

Another example of how language affects our expectations about treatment and prognosis is the diagnosis of Degenerative Disc Disease, which is a common diagnosis that people have come to expect they will be given as they age. “Degenerative” suggests that there is a slippery slope and that the only way is down. Indeed, the term “degenerative cascade” is often used to describe what happens, as though we will become exponentially worse with time. “Disease” suggests that we are sick, that we have caught something. The very name of the diagnosis sets up an expectation that we are never going to get better.

What would medicine be like today if we were not thinking of the body as a machine or the mind as a computer? That question is only partly rhetorical, as what I am proposing here is a different concept of how the body functions, particularly the musculoskeletal system (see also Rogel, 2010). No one can predict the consequences of changing our point of view in this way, but we do have a clue about how things could be different by looking at Oriental Medicine. Oriental Medicine does not view the body as a machine, and it has come up with a totally different treatment strategy. Changing our language is a useful starting point.

What I will propose here is a way of viewing the body that does not presuppose a degenerative process as the inevitable response to injury. I believe we have been overlooking the role ligaments play in how our joints function. By viewing ligaments as something more than static connectors of bones, we can begin to think about the body as an integrated whole with the ability not only to become worse but also to become better.

## The Importance of Gait

In my opinion, gait is the key to understanding orthopedic problems, whether we are talking about the human body or the bodies of other vertebrates. Pretend that you are walking

*(continued on the next page)*

## The Making of a “Structural Functionalist”

Each of us is shaped by the time and place in which we live; and we, in turn, make our marks on our historical times and places. My ideas about how the body works are very much rooted in my personal experiences – as a patient, as a practitioner, as a person living in Illinois at the turn of this millenium, and as the recipient of a very special treatment table from an unknown giftor.

Soon after I graduated from acupuncture school in 1986, acupuncture became a Class 4 felony in Illinois, with penalties equivalent to kidnapping. Living with the threat of being charged with a felony had a profound effect on how I practice acupuncture. I made sure that everything that I could do with a needle I could also do with my hands. It took us 14 years to change the law in Illinois.

People often ask me what I “do.” I say that I am an orthopedic acupuncturist, but what I actually do is hard to define. I use many of the methods of Eastern Medicine – acupuncture, topical herbal preparations, moxibustion, manual therapy, tuning forks – but I use them because I am trying to align the joints. One of my colleagues called me a bone whisperer, and I think that best describes what I “do.”

I listen to bones, ligaments, and tendons with my fingers and try to line up the tissues in the way that they most want to be lined up, which allows the bones then to move to a position where they are aligned and can move more freely. How I developed my concepts and methods, how I became a bone whisperer, was a slow process. It began with problems that I had with my own hip and my own neck. For years I went to chiropractors and osteopaths and did not really get much help. Then at about the same time I started acupuncture school, I started treatment with a new osteopath. It turned out that he was also an acupuncturist, and his treatment turned my life onto a new path.

Not only did he work on my neck, he also lined up my eyes and straightened my teeth – with his hands. I was not aware of what he had done until I saw myself later in a mirror. His treatment showed me that it is possible to make profound changes in the alignment of the body, painlessly, without fanfare, and with one’s hands. This experience started me on a quest to learn how joints work because I wanted to be able to help others in the way that he had helped me.

After graduating from acupuncture school, I started studying orthopedics with various teachers. What I realized fairly soon was that I was being taught structure – something very static, very concrete,

*(continued on page 8)*

the names of things, the locations of things, kinds of fibers and cells. It was hard to understand, and I found that this information was not useful. What I really needed to learn was function, how the joints work; and I found that I had to learn that on my own. It took me about ten years to figure out how the body really works, ten more years to get pretty good at using that information to treat my patients, and ten more years to learn how to teach others how to do what I do. I am still learning. In the process, though, it surprised me to realize that other people do not see what I see. Once the genie is out of the bottle, it cannot be put back in. My way of thinking has been changed forever, and I would like to share what I see. I think there is a lot more that medicine – both Western and Eastern – could be doing to help people with orthopedic problems. I think we are not seeing things that are right in front of us. We have our cultural assumptions that the body is like a machine. We look at it in a fragmented way. When a part “wears out,” we “replace” it. But the body really is not a machine. It is an amazing, dynamic, adaptable, plastic construction.

Now, about my table. Before I started acupuncture school, I had made arrangements to live overseas for a year and a half, so I took a planned leave of absence during my first year in school. While I was gone, I sublet my apartment to two of my acupuncture classmates. When I returned, they were gone, and in my apartment was an incredible treatment table. Instead of the typical folding massage table, this was a tall narrow table made of square-tubular steel. It is enormously heavy and sturdy, and there is a three-step, two-level stool that goes with it. I can do anything with this table! I can stand on it if I want, along with the heaviest patient, without fear that it will collapse. I can use body mechanics to move people all around on the table and never worry that the table will tip over. It has a solid wood platform with a relatively thin padding that is very comfortable for patients, yet I can place my fingers under patients and use the solid wood to brace my hands as I work. It is narrow, so I am never far from my center of gravity as I lean over patients. Without this table, I would never have been able to develop the treatment techniques that I use. I am eternally grateful for this gift; and, in turn, I wish to pass along what I have learned about how bodies work, as a result of having worked on this table, in this historical time and place, with my own personal treatment experiences, and from thirty years of working on patients, each of whom was a personal teacher to me and who validated what I am about to share with regard to how our plastic bodies work. ♦

or jogging or marching in a band – or actually get up and take some steps – and then stop yourself mid-stride with your right knee in the air. Lifting your right leg rotates your right pelvis backward and outward. The leg on which you are standing, your left leg, rotates inward at all its joints, taking up the slack, so that you have a solid column on which to stand. As we walk, we swing our arms, partly to maintain balance, partly to create momentum. When your right leg is lifted, your right elbow moves backward, rotating your right shoulder forward; and your left shoulder rotates inward in a way that is very similar to what your left leg is doing. The head is also involved in walking, even though we are not usually aware of it. When you lift your leg, your head rotates and tilts to counterbalance whatever is happening below. As we walk, we alternate from side to side, and so what I have just described for the right side will become the left side as we change from leg to leg. As we examine what happens to the joints in response to injury, it will be helpful to remember this image, or perhaps even to get up and start walking and observe what is happening with your joints and body parts.



*It's All About Gait. All the joints of the body are involved in maintaining balance during gait. Father and son are at the same point in the gait cycle. Notice that the father's body mechanics have accommodated to a problem in his lower back, and his body does not move as completely through the gait cycle as his son's body does. Photograph used with permission from Kenneth Hadley Schroeder, photographer, and from subjects in photo.*

## Keys to the Kingdom

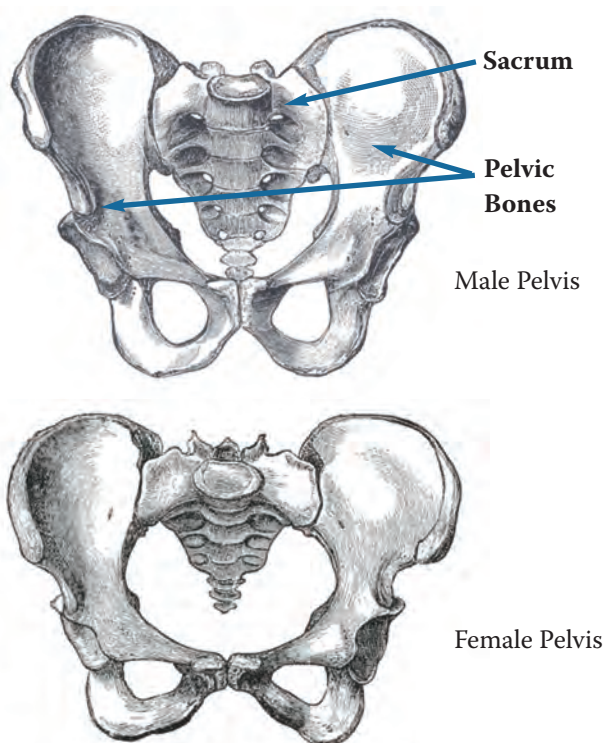
### 1. The Foundation

I consider the pelvis and the lower lumbar vertebrae to be the Foundation of our bodies, much like the foundation of a house. It is the place in the middle of our bodies to which everything connects. Problems in the Foundation affect every joint in the body. When the pelvis and lower

*(continued on the next page)*

lumbar spine are asymmetrical, the joints of the lower extremities alter themselves to accommodate to the asymmetry. Likewise, injuries in our lower extremities affect the balance and function of the Foundation, in the same way that the condition of pilings will affect the stability of a tall building. The Foundation and the lower extremities function as an integrated unit. Sometimes it is impossible, and irrelevant, to identify whether a problem begins in a sacroiliac joint, a hip, a knee, or a foot. Wherever the problem began, all joints participate in the accommodation. In similar fashion, imbalances in the Foundation and lower extremities must be counterbalanced by the position and function of the upper extremities. When the imbalances are so severe that they can no longer be counterbalanced, we resort to assistive devices such as canes, walkers, and wheelchairs.

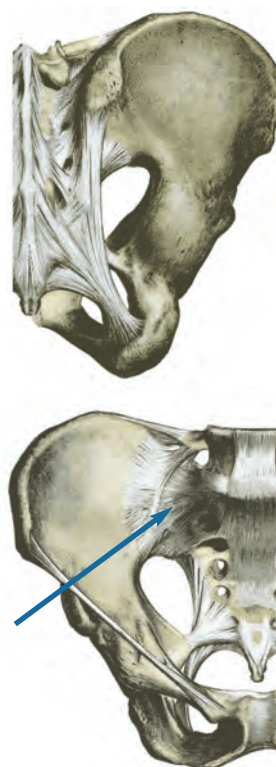**Figure 1a: Pelvic Girdle**



The pelvis is made up of three bones – the two pelvic bones that we sometimes call “hips” and the sacrum between them at the base of the spine (Figure 1a). These bones are connected to each other by ligaments, which are exceedingly strong in this part of the body. For this discussion, I am going to focus only on the sacroiliac joint ligaments; but it is important to understand that there are other pelvic ligaments as well that are very important for how we move and how we function.

The sacroiliac joints are located where the two pelvic bones and the sacrum come together. As you can imagine from the way it is constructed, the weight of the entire upper body is on the sacrum, pushing down on the sacroiliac joints from above. Likewise, when you are standing, all the pressures from below push up through your legs into your sacroiliac joints. The pressures from above and the pressures from below meet at the sacroiliac joints, each of which is held together by three ligaments – the anterior, posterior, and interosseus sacroiliac ligaments (Figure 1b). That is why the ligaments in these joints are so very, very strong. They have to withstand walking, running, jumping, and whatever other movements we decide to do; plus they carry our bodies around. Some of us weigh hundreds of pounds, and yet these ligaments can carry us.

**Figure 1b: Anterior and Posterior Sacroiliac Ligaments** (*interosseus sacroiliac ligament is not pictured, as it is difficult to illustrate*)



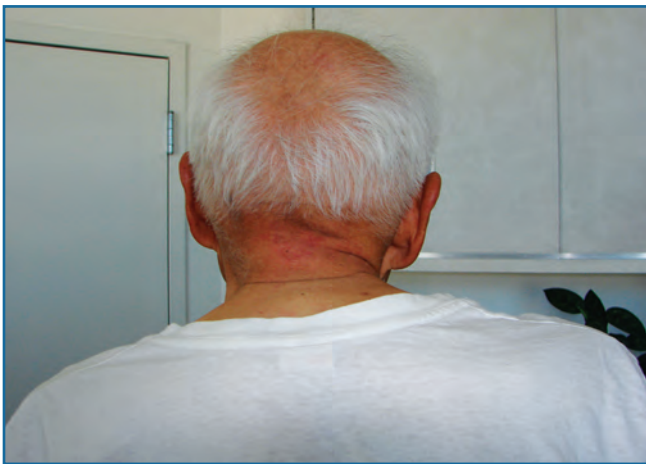**Upper:** Posterior sacroiliac ligament. Note that this ligament has many fibers of various lengths going in various directions.

**Lower:** Anterior sacroiliac ligament. This image shows many different pelvic ligaments. The arrow identifies the thin, fan-like fibers of the anterior sacroiliac ligament.

Orthopedic problems in the lower body typically begin with an injury to one or both sacroiliac joints (and, therefore, to the sacroiliac ligaments), either by direct injury to the joint or as the result of pelvic adaptations to an injury somewhere in the lower extremities.

*(continued on the next page)*

Typically the sacroiliac ligaments contract and stay contracted, whether the joint is injured by compression, as when we fall on it or when we have a foot on the brake at the moment of impact in an auto accident, whether it is injured by overstretching, as when we slip and catch ourselves, or whether an injury in the lower extremity restricts the movement of the sacroiliac joint during what should be a normal gait cycle. Ligaments behave somewhat differently from muscles and do not relax by themselves. Massaging the muscles does not relax the ligaments, and most people are unable to relax ligaments voluntarily. Some people have learned to relax ligaments by stretching them. When the ligaments of the sacroiliac joint do not relax, they restrict normal movement through the gait cycle and hold our bodies in the walking position even when we are lying down or sitting. If we could get rid of the contractions, if we could realign the sacroiliac joints and restore their motion, then the body could relax into its neutral position; but, since it does not happen on its own, we carry these injuries through our lives, and we see the repercussions throughout our entire bodies.



*This 85-year-old man is seated. Notice that his body is locked in a position very similar to what it would be if he were walking. Photograph from the author's collection, used with permission from the subject.*

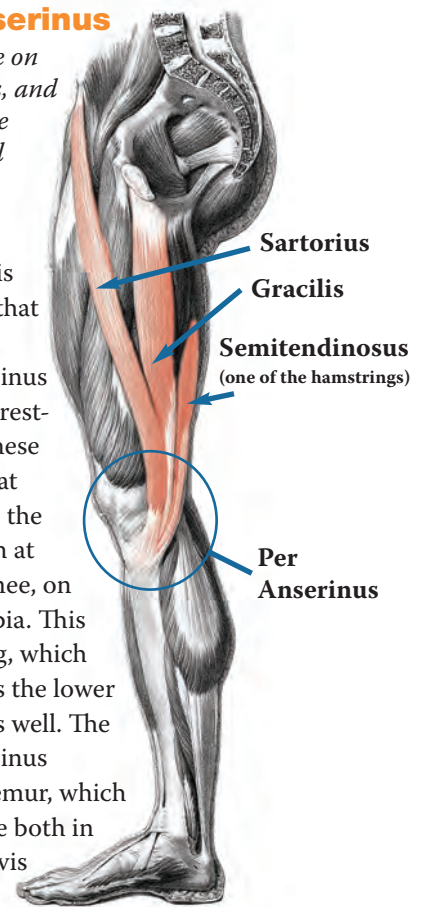
## 2. The Knee

Assuming that there is an injury in one or both sacroiliac joints, we can trace how this injury affects motion in other parts of the body by examining the muscles that attach to the pelvic bones. Even though we talk about the muscles as movers, muscles are pulled by bones. Muscles can only stretch a certain distance before there is a tug that comes from being attached to a bone. We need to look at the position of the bone in order to understand what the muscles are doing and what they can do.

### Figure 2a: Pes Anserinus

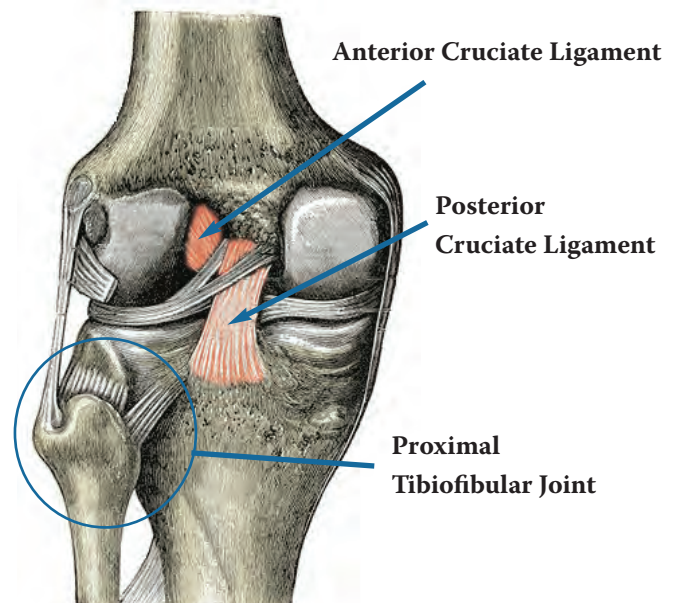
*Three muscles that originate on the pelvis (sartorius, gracilis, and semitendinosus) insert at the same location on the medial surface of the tibial head, bypassing the femur.*

On each half of the pelvis are three main muscles that interest us. They are the muscles of the pes anserinus (Figure 2a). What is interesting about them is that these three muscles originate at three different places on the pelvis, but they all attach at the same place on the knee, on the medial side of the tibia. This means that lifting the leg, which rotates the pelvis, causes the lower leg, the tibia, to rotate as well. The muscles of the pes anserinus completely bypass the femur, which is therefore free to rotate both in the hip socket of the pelvis and in the knee joint.



### Figure 2b: Cruciate Ligaments

*Anterior and posterior cruciate ligaments cross each other on the inside of the knee, allowing the femur and tibia to rotate on each other. The illustration also shows the gliding joint at the proximal tibiofibular articulation (superior tibiofibular joint).*



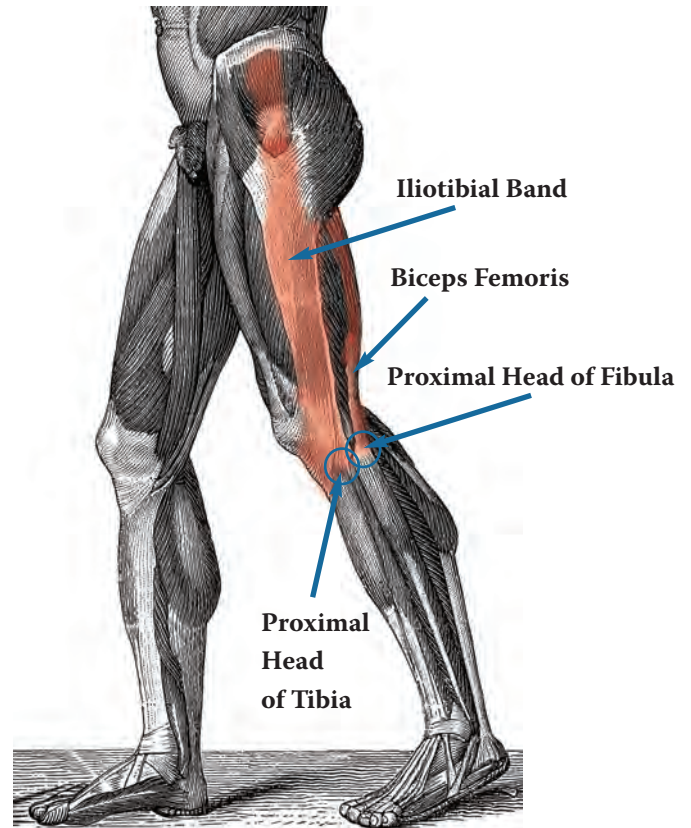
The knee is constructed in a very interesting way. It has ligaments on the inside that cross each other. These two ligaments, the cruciate ligaments (Figure 2b), allow the two bones of the knee, the femur on top and the tibia below, to rotate in relation to each other, which is exactly what happens when we walk. As the pelvis moves, the pes anserinus pulls up on the tibia, which then rotates in relation to the femur inside the knee joint capsule, which is ligamentous.

What keeps these ligaments, both the cruciate ligaments and the knee joint capsule – but especially the small cruciate ligaments – from ripping apart? What keeps the pelvis from pulling the knee to a position that it cannot tolerate, and tearing the cruciate ligaments? We know that they can tear; cruciate ligament tears are a relatively common injury when the knee is twisted with too much force, as can happen with sudden changes of direction while running. But these injuries do not occur in normal walking. Why?

The reason is that the fibula, the thin bone on the outside of the lower leg, is connected to the tibia by a gliding, synovial joint called the superior, or proximal, tibiofibular joint (Figure 2b). It is structured and positioned in such a way that the head of the fibula snugs up against the head of the tibia as the tibia rotates, and it prevents the tibia from rotating excessively. It is really an ingenious system. When there has been an injury in the sacroiliac joint that prevents the pelvis from moving completely through the gait cycle, the fibular head, in effect, becomes “stuck” at one or the other end of its glide, and it stays there because the pelvis cannot move symmetrically through the entire gait cycle. The knee does not fully return back to neutral when the leg is straight. I see this in patients all the time. Typically, the proximal fibular head is “stuck” in the anterior position on one side and in the posterior position on the other side. Patients often are not aware that there is a problem until I press on the tibiofibular ligaments, which typically are sore. This is one of the most common sources of knee pain that I see clinically. Regardless what imaging may show about the inside of the knee, my patients more often complain about pain at the pes anserinus or at the proximal tibiofibular joint – both on the outside of the knee – than they do about the structures on the inside of the knee joint.

### Figure 2c: Iliotibial Band and Biceps Femoris (Hamstring)

*A tight IT band or hamstring results from the position of the pelvic bones.*



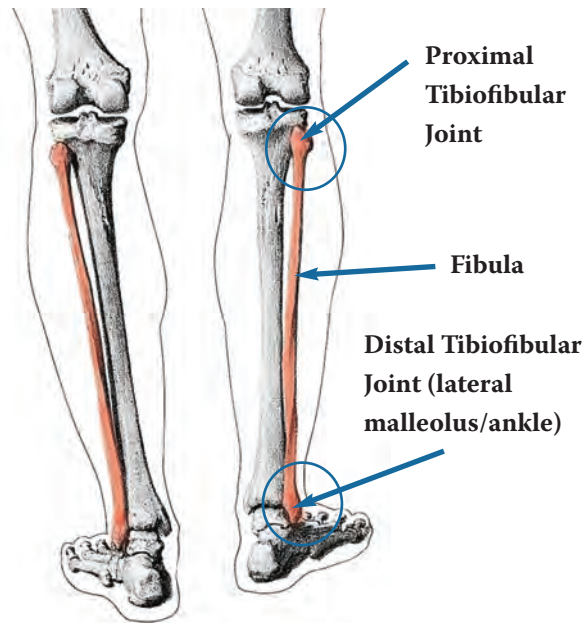
Restrictions in the pelvis and the proximal tibiofibular joint set up tight iliotibial (IT) bands (IT bands attach to the tibia) and tight hamstrings (the biceps femoris attaches to the fibula). Figure 2c illustrates how the IT bands and the hamstrings are affected by the positions of the pelvis and the knees. When I see a tight IT band or a tight hamstring that will never relax, I see a problem somewhere in the pelvic girdle. The solution to the tight hamstring or IT band is to mobilize the sacroiliac joints, realign the pelvis, and mobilize and realign the knee and fibula. If we only relax the hamstrings, or if we only work on the IT band, we will never fix the problem and we will have to keep loosening them for the rest of our lives because the problem is not the hamstring or the IT band itself. The hamstring and IT band are symptoms of another problem which is occurring in the pelvis, most likely in the sacroiliac joints or a problem in the leg that affects the way the sacroiliac joints work. Either way, the entire pelvis and both lower extremities need to be treated in order to deal with the problem.

*(continued on the next page)*

### 3. Foot

#### Figure 3a: Fibula

The fibula starts at the knee and ends as the lateral malleolus (external ankle bone).

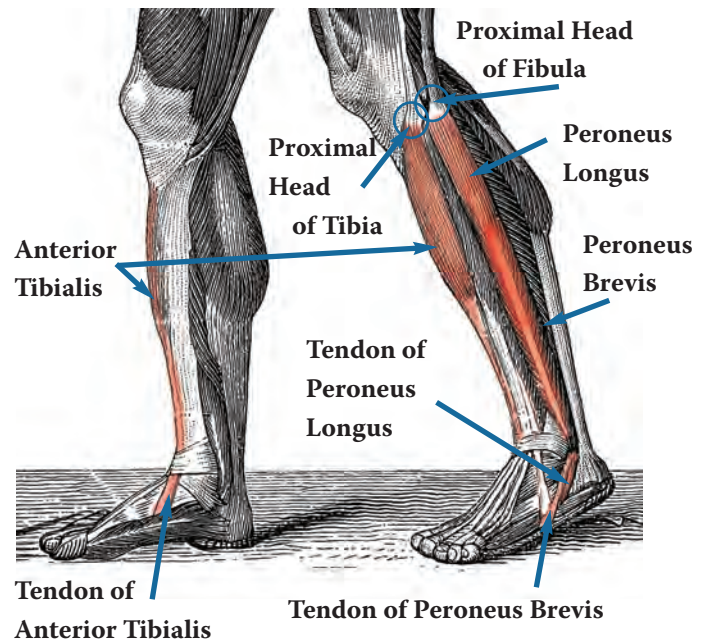


As we work our way down the leg to the foot, we follow the fibula. The other end of the fibula is the outside ankle bone, the external malleolus (Figure 3a). It forms a very different kind of joint at the ankle than we found at the knee. The knee can move in many directions; it can flex and extend, rotate internally and externally, and sidebend medially and laterally, and it can be compressed and tractioned. The proximal tibiofibular joint glides with these movements. In comparison, when you rotate your ankle, you are mainly rotating your foot. The fibula and the tibia form a mortise joint over the talar bone of the foot to create the ankle joint, which is basically a hinge. The ankle itself is very stable and has relatively little mobility compared to other joints.

The foot, on the other hand, is constructed of many bones. I think there is a very interesting reason for this. I see the foot as the end of the line in terms of accommodation to problems that come from the pelvis. When the pelvis rotates as we lift a leg, the three muscles that attach to the pelvis and form the pes anserinus at the knee transfer pelvic movement to the tibia. Since these muscles are not attached to the femur, the femur rotates in the hip socket and at the knee. When the tibia rotates at the knee, it pulls on muscles that attach to the foot, and it moves the proximal tibiofibular joint, with its ligaments. We are interested in the actions of three of the muscles that are affected by this movement (Figure 3b).

#### Figure 3b: Anterior Tibialis and Peroneus Muscles

The Anterior tibialis originates on the tibia and the Peroneus longus originates on the fibula. Both insert under the foot on the proximal head of the first metatarsal. The Peroneus brevis also originates on the fibula, but it inserts on the proximal head of the fifth metatarsal.



The anterior tibialis is the muscle that comes down the outside of the shin bone, the tibia. It attaches along the upper two-thirds of the tibia; when it gets to the ankle, it crosses medially and attaches under the bottom of the foot at the medial cuneiform bone and the proximal end of the first metatarsal, which is the largest of the long bones in the foot, supporting the big toe. Its action is to dorsiflex the ankle and pull it into inversion, and to balance the leg and ankle on the foot when weight bearing.

Two other muscles come down the outside of the leg from the knee, in parallel with the anterior tibialis. However, instead of attaching to the tibia, they attach to the fibula. The peroneus longus attaches to the superior head and upper two-thirds of the fibula, basically right behind the anterior tibialis. The two muscles come down in parallel but originate on different bones. When the anterior tibialis crosses the ankle to attach to the medial cuneiform and first metatarsal from the medial side of the foot, the peroneus longus continues down the outside and goes behind the lateral malleolus and under the lateral side of the foot to attach to that same place on the medial cuneiform and the first metatarsal where the anterior tibialis attaches. So we have this amazing pulley system

between the knee and the foot. We have two muscles coming down in parallel from the outside of the knee. When they get to the ankle, one goes to the medial side of the foot, the other goes to the lateral side of the foot, and they both attach at the same place under the bottom of the foot. Rotating the knee pulls on both of these muscles at the same time; and because these tendons attach underneath the foot from opposite directions, they pull up on the foot. The anterior tibialis dorsiflexes and inverts the ankle; the peroneus longus plantarflexes and everts the ankle.

The third muscle in this system adds an important little twist that helps to explain variations between the two feet as well as some of the problems we experience in our feet. The third muscle is the peroneus brevis. Like the peroneus longus, it attaches to the fibula; but instead of attaching at the proximal end, it attaches on the lower two-thirds. Also like the peroneus longus, it continues down the outside of the foot and behind the lateral malleolus after the anterior tibialis crosses medially. Instead of crossing under the foot to attach to the first metatarsal, on the medial side of the foot, it stays on the lateral side of the foot and attaches to the fifth metatarsal, the one that supports the little toe. So we have two muscles that originate on the same bone, the fibula; one continues to the medial side of the foot, and one stays on the lateral side of the foot. Like the peroneus longus, the peroneus brevis plantarflexes and everts the foot.

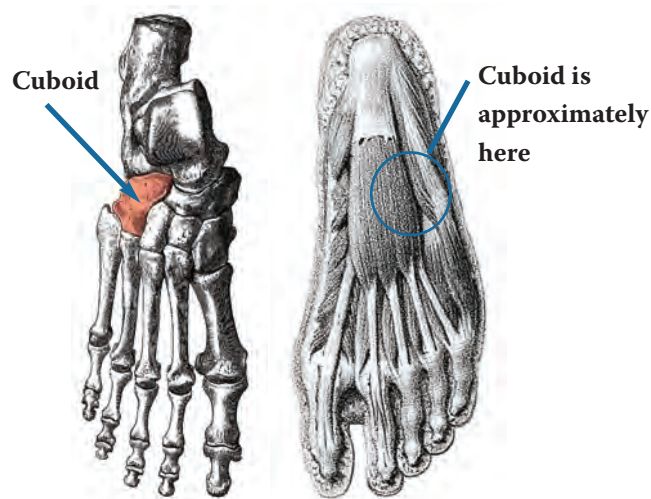
When the tibia rotates, two actions occur. One pulls the proximal head of the first metatarsal upward, and one pulls the proximal head of the fifth metatarsal away from the first metatarsal and flattens the arch. You can see and feel this action if you stand and rotate from side to side. Watch how your feet move. When you rotate to the right, your first metatarsal on the right foot lifts and your ankle inverts. When you rotate to the left, that same first metatarsal moves downward, your arch flattens, and you can see your foot appear to spread. This is known as pronation, and it is a normal part of the gait cycle. If you watch your foot as you walk in place, you can see this same action occurring.

Seeing how much motion in the foot originates from higher up in the leg, it begins to make sense why we have so many little bones in the foot. As the peroneus and anterior tibialis muscles pull on the arch, all the little bones in the foot move – not a lot, but enough so that the foot can accommodate to the many movements the leg can make. Problems occur when there is an injury that never heals or a problem that never goes away, because then the foot cannot move through its portion of the entire gait cycle. As you might expect from what I have

said above, the inability of the foot to move through the entire gait cycle is not a cause but rather a symptom of a problem higher up.

### Figure 3c: Cuboid Bone

*Left image: Bones of the foot as seen from above, with cuboid identified. Right image: View of some of the muscles, tendons, and fascia on the bottom of the foot, with the approximate position of the cuboid bone marked.*



When the fibula and tibia lock in rotation because of a problem in the pelvis, the peroneus and anterior tibialis muscles constantly pull on the first and fifth metatarsals, pronating the foot and spreading the bones of the arch and allowing the bones of the arch, particularly the cuboid bone, to push down into the plantar tendons, the plantar fascia, and the plantar ligaments (Figure 3c). If the bones in the arch become wedged in such a way that they cannot move upward to relieve the pressure on these tissues, the tissues become irritated, producing what we call plantar fasciitis. In my clinical experience, if I can calm down the tissues enough to realign the bones in the arch, particularly the cuboid bone, the plantar fasciitis goes away. Complete treatment requires working up the leg to restore alignment in the knee, hip, and pelvis, as well as in the foot and ankle.

Many other kinds of problems also occur in the foot because of the way the foot accommodates to problems higher up in the leg and pelvis. A femur that is constantly rolled out because of pelvic torsion encourages bunions to form. The challenge in walking is to carry the weight of the body over the ball of the foot and the toes. When the femur is rolled out at an angle, it is more efficient to pass the weight of the body over the distal head of the first metatarsal than it is to pass the weight over the ball of

*(continued on the next page)*



the foot. Bones and other tissues reshape themselves according to how we use them. When we use the distal head of the first metatarsal for weight bearing with every step, the body moves the toe out of the way and lays down more tissue at the distal head of the metatarsal, forming a bunion. Removing the bunion surgically may create a more esthetically pleasing foot, but it does not remove the problem that created the bunion in the first place. Consequently, the body creates a new adaptation, sometimes another bunion, sometimes a permanent shift in the arch, sometimes problems in the toes, depending on what type of bunion surgery was done and what other problems exist in the pelvis and lower extremities.

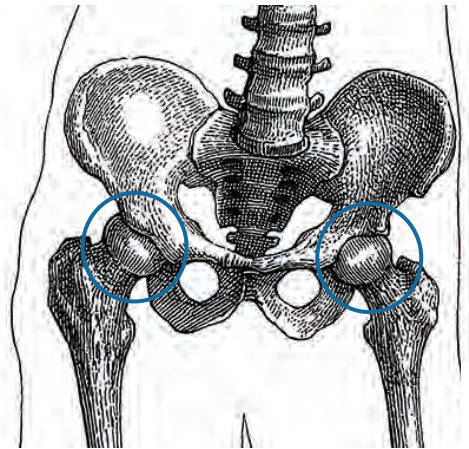
The spreading of the metatarsals and flattening of the arch can create other problems in the feet as well. Calluses occur when bones press tender tissue against something, such as the side of a shoe; the callus is the body's attempt to create a protective barrier. Neuromas are a similar protective mechanism. One can think of them as calluses on nerves. They occur when bones rub on a nerve. Hammertoes also form in response to a change in the shape of the arch. When the metatarsals cannot function properly, toes will shift position, sometimes becoming stuck in flexion or crossed over another toe. In my experience, the way to fix hammertoes is to restore the arch of the foot, realign the metatarsals so that they move properly, and mobilize each of the toe joints. Again, problems in both extremities and the pelvis also need to be addressed, since the problems in the foot are the result of adaptations to what is happening above. If the problems higher up are not addressed, the problems in the feet are likely to return. Fractures, bursitis, tendinitis, and heel spurs have similar origins. The longer the adaptation has been in place, and the more permanent changes that have occurred, the more difficult it is to restore motion to all the joints in the foot. At a certain point, it may become impossible.

I see the foot as the end of the line in terms of accommodation to problems occurring anywhere in the lower body. The pelvis and lower extremities must be viewed as a unit, for they function as a unit. A problem anywhere in that system will create changes in all the joints of the lower body – and in all the joints of the upper body as well. If we use surgery to fix problems in the foot, then we cement these problems in place, in many ways, because these problems frequently are not really foot problems. They are usually accommodations to problems occurring higher up in the lower extremity and Foundation. When we cut a bone, such as a bunion, for example, we are taking away a symptom. Since the problem is still there, the body must find some other way to accommodate to the original problem, and it does.

## 4. Hip

### Figure 4a: Pelvis with Head of Femur in Hip Sockets

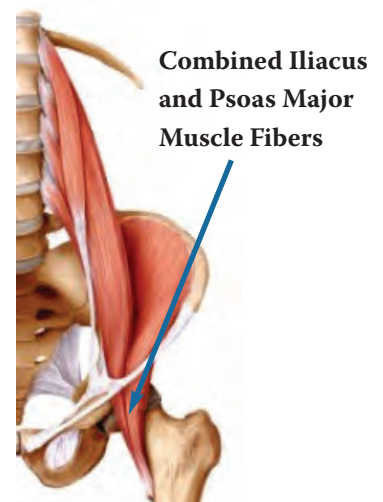
Returning to the pelvis, the Foundation, we will now explore what happens in the upper body. First we need to see how the lower body and upper body communicate with each other.



The heads of the femurs are located in sockets in the pelvis, where they are free to rotate according to whatever motion the pelvis is making (Figure 4a). When the pelvis rotates in gait, it moves a muscle, the iliacus, which originates on the inside of the pelvis and inserts onto the lesser trochanter of the femur, just outside the hip capsule. The backward motion of the pelvis pulls up on the femur, rotating the hip in its socket. A second muscle, the psoas major, also attaches to the lesser trochanter of the femur. When the pelvis moves the femur, the motion of the femur also pulls on the psoas major, which attaches to the front side of the spine on each of the five lumbar vertebrae (Figure 4b). Rotation in the hip creates rotation in the lumbar spine, beginning the process of rotation in the upper body in response to movement in the lower body. Rotation in the upper body counterbalances rotation in the lower body, allowing us to maintain our balance as we move through space and time.

### Figure 4b: Iliacus and Psoas Major Muscles

*Iliacus originates on the inner surface of the pelvis, and psoas major originates on the vertebral bodies of L1-L5. Their intermingled tendon fibers insert on the lesser trochanter of the femur.*



Hip problems tend to show up as wear and tear in the hip socket. If the pelvis is unable to move back to its own neutral position, there is going to be constant wear in the hip socket. That is how a hole gets worn on the inside of the hip socket and people end up needing joint replacements because the cartilage has worn away to the point where it starts wearing away the bone. If we could somehow manage to straighten out the pelvis and take the pressure off the hip socket, then we would not have to worry so much about needing joint replacements.

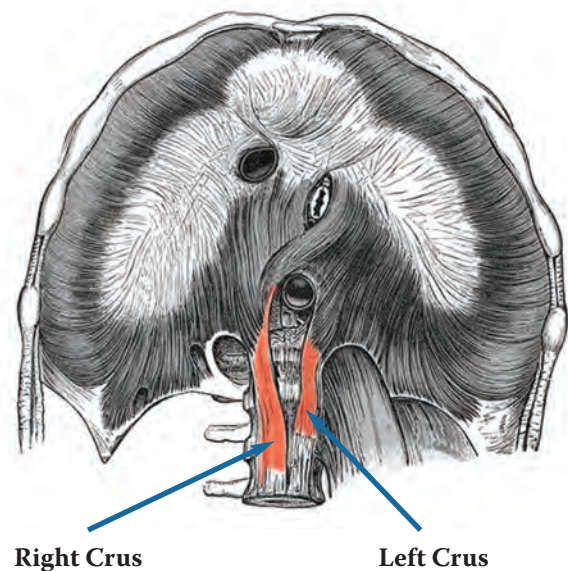
I recognize that I am speaking about the action of the bones and the muscles in a somewhat different way from usual. We talk about the muscles as though they move the body. Certainly, without muscles we would not move; but without bones we would not move either. We cannot separate the muscles from the bones. Yet our speech, and the way we think, gives primacy to the muscles over the bones. I am switching the primacy to the bones as I describe to you what I see happening in the body. Bones place limits on muscles in a way that muscles do not place on bones. Bony structures are hard and do not give. Muscles stretch and will accommodate to a wide range of bone positions. For these reasons, I speak of the bones, rather than the muscles, as the prime movers, recognizing that there is a dynamic interaction between them and that we need both to be able to move.

Rotation of the lumbar vertebrae in response to pelvic motion, via the psoas major, triggers another ingenious mechanism involving the diaphragm. The diaphragm has two tendons that attach onto the anterior surfaces of the lumbar spine. The right side tendon (right crus) is larger and longer and attaches to the anterior surfaces of L1, 2, and 3, while the left side tendon (left crus) attaches to the anterior surfaces of only L1 and 2 (Figure 4c). When the lumbar vertebrae rotate, they pull on these diaphragm tendons. I believe the asymmetry in the attachments creates a type of stored tension that produces swinging in the upper body in response to pelvic motion, something like the spring in a clock mechanism that is driven by the swing of a pendulum. Walking and running are much easier when we allow our arms to swing. People who have sacroiliac joint problems or asymmetrical lower extremity restrictions do not swing their arms symmetrically through the gait cycle (recall the father in Photograph 1). My guess is that they find walking to be more of a “chore” than people who can swing their arms.

*(continued on the next page)*

### Figure 4c

*Underside of the dome of the diaphragm, showing right side tendon (right crus) attaching to L1-3 and left side tendon (left crus) attaching to L1-2, and showing the various conduits passing through the diaphragm. Note that the illustration does not clearly indicate the ends of the crura, even though Gray (1918) described the crura as being different lengths in his accompanying text to this illustration.*



### The Intriguing Mystery of the Diaphragm Tendons

One of the factors that helped me see the pattern I am describing as the “Keys to the Kingdom” is the similarity in the pattern across people. Certainly there is individual variation, but when all is said and done, most people exhibit the same pattern, regardless of their Western Medicine diagnosis. The most prominent symptom may be at the wrist or at the elbow or at the shoulder, but the prevailing pattern is the same in almost everyone. Even when the pattern seems to be different, once I have treated the most prominent symptom, the familiar pattern appears.

The question is why? While I cannot answer this question definitively, I have an hypothesis. I believe the answer lies somewhere in the difference in the lengths of the diaphragm tendons that attach into the lumbar spine, which can be seen in Figure 4c as attaching to L1-2 on the left and L1-3 on the right. If you look at versions of this illustration done by different artists, you will notice that not all artists draw this illustration the same way. Some attach the tendons to different vertebrae, say L1-2 and L1-4, or L1-3 and L1-4, and some attach both tendons to the same vertebra. What is correct?

*(continued on page 16)*

A colleague, Rachel Proud, LMT, who co-teaches some of my continuing education classes on the Keys, visited the International Museum of Surgical Science in Chicago, where 31 cadavers were on display. The Museum since has changed its exhibits, and the cadavers are no longer there. However, Rachel was able to see the lumbar attachment sites of the two diaphragm tendons on 30 of the 31 cadavers. The diaphragm tendons were identical on all 30 cadavers. The right crus inserted onto the anterior surface of L1-3, and the left crus inserted onto the anterior surface of L1-2, as illustrated in Figure 4c.

It is reasonable to ask whether the position of the tendons has any relation to handedness. Of course, there is no way to know whether a person who has died was right-handed or left-handed; but we can make an estimate from the statistics on hand dominance. According to a website produced by Luke Mastin, the incidence of self-reported left-handedness in developed Western countries stabilized at 12% by around the middle of the 20th century, when schools stopped systematically forcing natural left-handers to use their right hands. The Wikipedia puts the figure at 10%.

If 10% of people are naturally left-handed, then we would expect three of the 30 cadavers to have been left-handed people. If handedness were in any way related to the length of the right or left diaphragm crura, then we would expect three of the cadavers to have a longer left crus and a shorter right crus. This was not the case, as all 30 cadavers had a longer right crus.

This is consistent with my clinical observations. I have noticed no difference in the pattern of the Keys according to the hand dominance of my patients. I see the same pattern whether I am treating right-handed or left-handed people. ♦

#### References

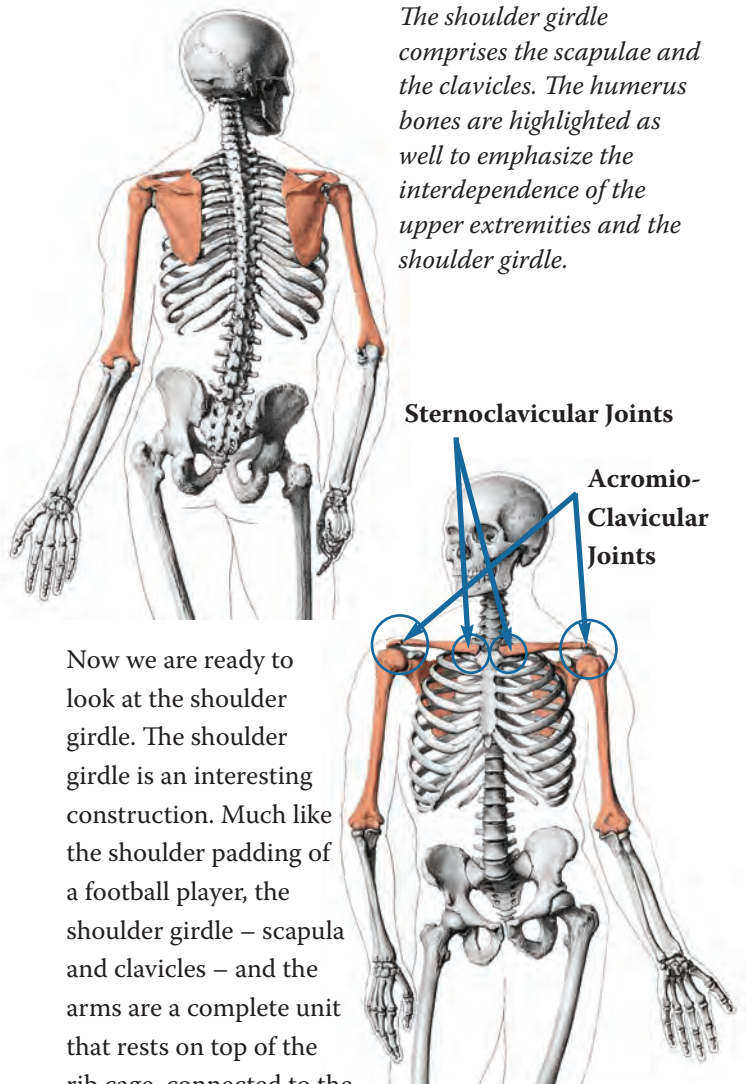
Mastin, Luke. <http://www.rightleftrightwrong.com/statistics.html>, downloaded 30 August 2015.

Wikipedia. <https://en.wikipedia.org/wiki/Handedness>, downloaded 30 August 2015.

The diaphragm is important for another reason. As can be seen in Figure 4c, many structures pass through the diaphragm, such as the aorta, the vena cava, arteries to the liver, and the esophagus. If the pelvis is unable to return to its neutral position, there will always be an exaggeration of the asymmetrical pull on the diaphragm from the right and left crura. Because this tension never releases, the diaphragm will always squeeze on the structures that go through it, like the esophagus or the blood vessels. I propose that this is the source of some of the internal medicine problems that we have such a hard time solving and that do not respond well to medication, like “essential hypertension.” I also suspect that this restriction of the diaphragm is involved in GERD.

## 5. Shoulder

### Figure 5a: Shoulder Girdle



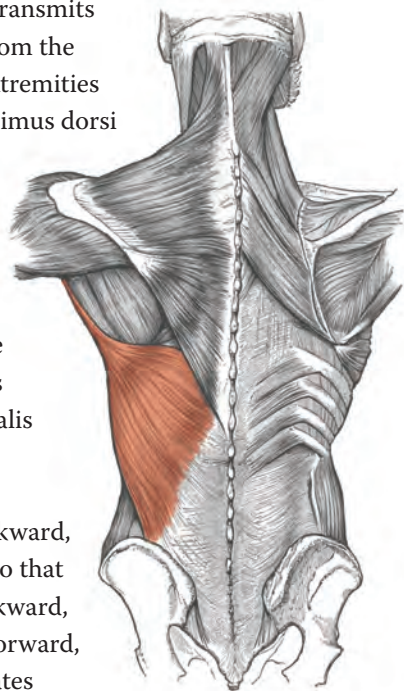
*The shoulder girdle comprises the scapulae and the clavicles. The humerus bones are highlighted as well to emphasize the interdependence of the upper extremities and the shoulder girdle.*

Now we are ready to look at the shoulder girdle. The shoulder girdle is an interesting construction. Much like the shoulder padding of a football player, the shoulder girdle – scapula and clavicles – and the arms are a complete unit that rests on top of the rib cage, connected to the rest of the skeleton by two small joints, the sternoclavicular joints (Figure 5a).

## Figure 5b: Latissimus Dorsi

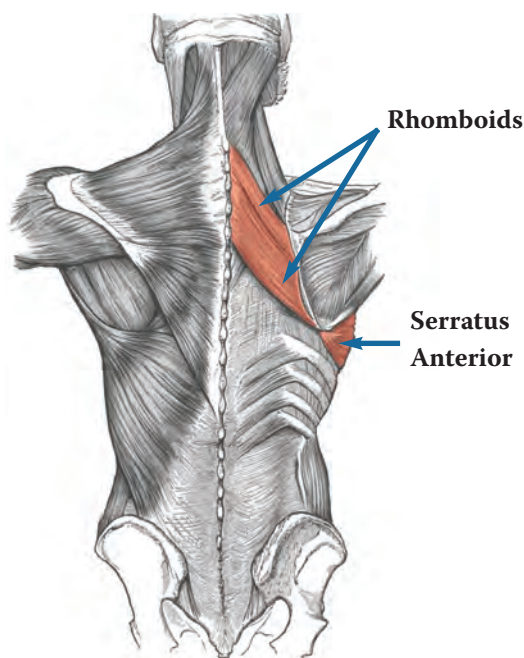
*The Latissimus dorsi directly transmits pelvic motion to the arms.*

The latissimus dorsi transmits movement directly from the pelvis to the upper extremities (Figure 5b). The latissimus dorsi originates from multiple sources, including the pelvis and sacrum, and inserts onto the humerus between the insertions of the teres major and the pectoralis major. Consequently, lifting the leg to walk rotates the pelvis backward, which pulls the arm so that the elbow moves backward, the shoulder moves forward, and the humerus rotates medially, which is our familiar arm-swinging motion when we walk or run. Movement of the pelvis, therefore, has a direct effect on the upper extremities.



## Figure 5c: Rhomboids and Serratus Anterior

*The rhomboids and the Serratus anterior anchor the scapula to the spine and rib cage.*

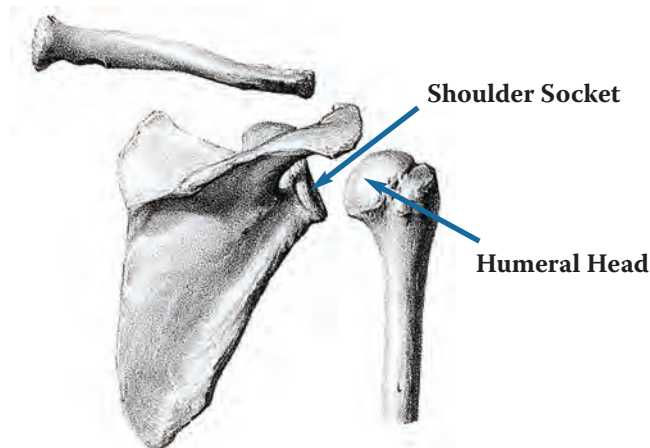


What keeps the shoulder girdle from falling off the body, say, for example, as we throw? I believe this safeguard is provided by the muscles that attach the scapula to the spine and rib cage, the rhomboids and the serratus anterior, respectively (Figure 5c). Both sets of muscles attach at basically the same place on the scapula, the medial border. The rhomboids pull the scapula medially toward the spine; the serratus anterior pulls the scapula laterally, away from the spine. Those of us who do a lot of work on shoulders find that these opposing muscles very efficiently immobilize the scapula when there are shoulder problems. Sometimes it is very difficult to release these muscles and restore motion to the scapula. In effect they are acting as a brake to prevent the shoulder from breaking, or falling off.

The shoulder joint is a very small joint when compared with other joints. It is not supported by a bony socket in the same way that the hip is. The hip socket is built for strength; the shoulder socket is built for mobility. Yet there is tremendous pull coming from very large muscles in the lower body onto this much smaller joint, and we use our shoulders to do very heavy work. Stabilizing the scapula is one thing, but what keeps the shoulder joint itself from pulling apart?

## Figure 5d: Shoulder Socket

*With humeral head separated from the socket and clavicle separated from the acromion process to illustrate the small size of the shoulder socket.*



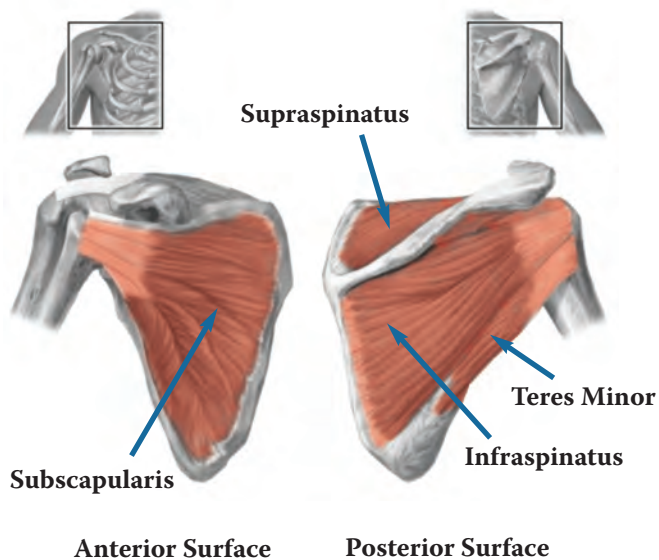
The shoulder complex is composed of three main structures, duplicated on each side of the body: the scapula, the clavicle, and the humerus. The actual shoulder joint is the place where the head of the humerus fits into a shallow socket in the lateral edge of the scapula (Figure 5d). The joint is held in place by a capsule composed of ligaments, by a shallow border of tough

*(continued on the next page)*

tissue around the socket called the labrum, and by the vacuum that occurs in all synovial joints. The delicateness of this joint, the forces we place on it, and our chronic asymmetry combine to make this joint the site of half of the major joint dislocations seen in emergency departments (Dislocated shoulder, Wikipedia, 2015), 95% of which are anterior dislocations, as would be predicted by the patterns I am describing in this article.

### Figure 5e: Rotator Cuff

*The rotator cuff is formed by the tendons of four muscles that attach from the scapula to the head of the humerus: Subscapularis (on the anterior surface of the scapula); Supraspinatus and Infraspinatus (on the posterior surface of the scapula); and Teres minor (on the lateral surface of the scapula).*



The scapula is basically a floating platform that is stabilized by the rhomboids and the serratus anterior in the back and various muscles in the front that act as guy wires. It is a flat bone that serves as an attachment site for an interesting array of muscles, including the muscles that are known as the rotator cuff (Figure 5e). Three of these muscles have large “footprints” on broad areas of the scapula; they end in thin tendons that attach to the proximal head of the humerus and help to support the shoulder socket. These three muscles are the infraspinatus, located in the fossa below the spine of the scapula; the supraspinatus, located in the fossa above the spine of the scapula; and the subscapularis, located in the fossa on the entire anterior surface of the scapula. The fourth muscle of the rotator cuff is the teres minor, which attaches from the lateral border of the scapula to the head of the humerus.

The attachments of these four muscles on the humerus form a “cuff” around the head of the humerus.

Rotator cuff tears are a common problem. In my opinion, a torn rotator cuff is a symptom of a problem that originates elsewhere, usually in the pelvis. When pelvic motion is restricted in a way that prevents the pelvic girdle from moving freely through the entire gait cycle, we see the consequences in the shoulder girdle, which also cannot move freely through the entire gait cycle. Because the shoulder socket is so much more delicate than the hip socket, we see more symptoms at the shoulder. For example, when the latissimus dorsi is always pulling the elbow backward, the head of the humerus is always pressing into the front part of the shoulder capsule, putting pressure on the ligament, but also on the tendons of the rotator cuff toward the front of the capsule. The tendon of the supraspinatus is particularly stressed because of how it is positioned within the structures of the shoulder, and it is a frequent site of rotator cuff tears. The rotation in the shoulder girdle and pressure on the front of the capsule can be seen even when the arms are hanging down at the sides at rest.

So what keeps the shoulder from pulling out of its socket? The stabilizing of the scapula by the rhomboids and serratus anterior are certainly part of the answer. The other parts of the answer come from two sources, I believe – the clavicle and the glenohumeral joint capsule. When the sacroiliac joint fails to move through its full gait cycle, it tends to become “stuck,” as it were, with the right pelvic bone pulled in a posterior or posterolateral direction. This pulls on the latissimus dorsi, which pulls on the humerus as described above. This means that the shoulder girdle is also restricted as it moves through the gait cycle. Typically, the right scapula becomes winged, with the inferior angle pulling away from the rib cage in a posterior direction, and the humeral head pushing into the front portion of the shoulder capsule. The left scapula and humeral head tend to internally rotate, lifting the medial border of the scapula away from the rib cage.

These motions affect the clavicles, which have joints at either end, the sternoclavicular joint (SCJ) at the sternum and the acromioclavicular joint (ACJ) at the scapula (See Figure 5a). These two joints are constructed a little differently, but both are planar joints with gliding motion. Just as the proximal fibular head can only glide so far before it stops, the same is true with the SCJ and ACJ. When they reach the end of their gliding surfaces,

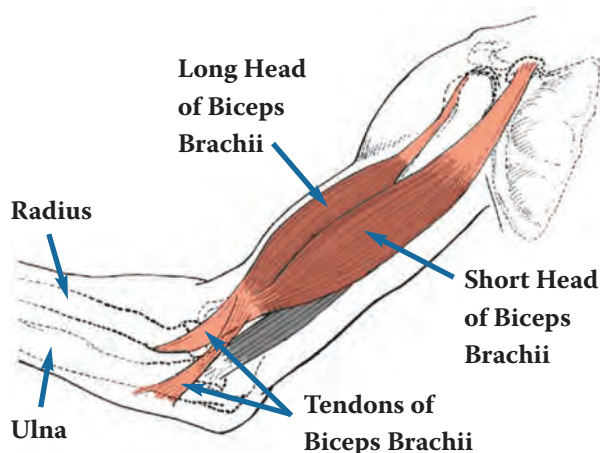
bone meets bone and motion stops, under normal use conditions. Clinically, I see that the right clavicle, in particular, tends to lock, as the acromioclavicular and sternoclavicular joints approach the limits of their ability to glide. As the humeral head presses anteriorly in the joint capsule, the ligaments tighten in response to slight misalignments and to the vacuum inside the joint. This process, along with reduced motion of the SCJ, the ACJ, and the scapula, eventually produces a frozen shoulder, which very effectively prevents the shoulder from falling off. Strain on the rotator cuff is a symptom that this process is under way.

## 6. Elbow

The scapula plays an important role not only in problems at the shoulder but also in problems farther down the arm. In the same way that we have two muscles coming down the side of the leg in parallel and attaching under the foot from opposite directions, we have a similar construction in the arm, with two muscles originating from different points on the scapula and inserting onto the forearm from different directions.

### Figure 6: Biceps Brachii

*The short head of the biceps brachii originates on the coracoid process of the scapula. The long head originates at the shoulder socket. Both insert on the radius and ulna of the forearm*



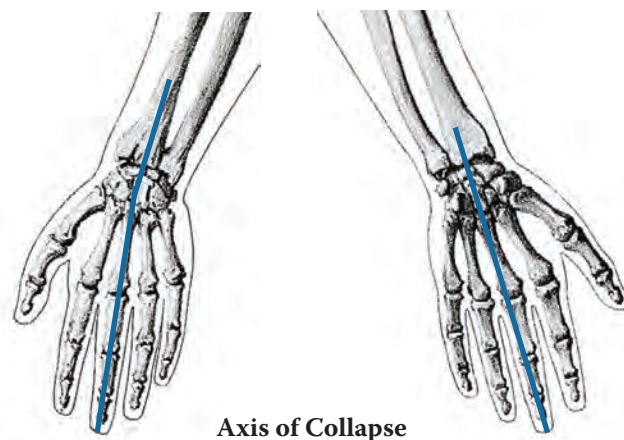
The scapula has a projection called the coracoid process that points anteriorly and supports six attachments, one of which is the short head of the biceps brachii (Figure 6). The short head of the biceps connects the scapula and the lower arm, skipping the humerus in the same way that the muscles ending at the pes anserinus connect the pelvis and tibia, skipping the femur.

The long head of the biceps makes a similar journey down the arm. It originates at the shoulder socket, which is located on the lateral edge of the scapula. The two heads of the biceps come down the arm in parallel, originating at slightly different places on the scapula and inserting on the forearm where the ulna and radius come together to form the elbow. Both heads of the biceps skip over the humerus. When the head of the humerus is always rotated anteriorly because of pelvic restrictions and counterbalancing shoulder torsion, the biceps is always stressed and pulls the ulna and radius toward the notch at the distal end of the humerus, restricting the motion of the forearm at the elbow. The constant pressure on the ulna and radius from the biceps brachii changes the positions of these two bones relative to each other and restricts their ability to rotate through their normal range during pronation and supination of the arm.

## 7. Wrist

### Figure 7: Wrist and Hand

*Bones of the wrist and hand tend to collapse around a central axis because of the way the ligaments cross at the wrist and pull the thumb medially.*



The inability of the radius and ulna to move freely around each other creates a similar situation in the hand as we have in the lower leg, where the bones of the feet shift to accommodate the pressures coming down from the pelvis. In the arm the pressures come up from the pelvis to the shoulder, rotating the humerus and scapula, pulling on the radius and ulna, and shifting the small bones in the wrist. Because of the way the ligaments are constructed, the hand tends to collapse around a central axis (Figure 7), creating problems such as carpal tunnel syndrome, trigger

*(continued on page 21)*

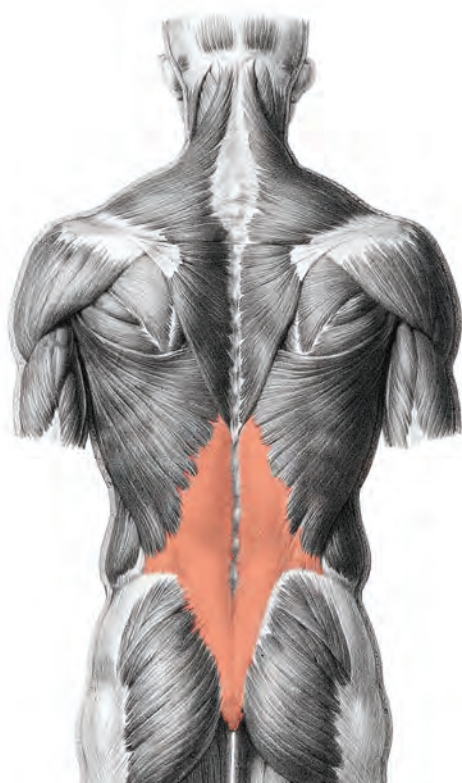
fingers, and De Quervain's tenosynovitis of the thumb. All of these various problems originate through the same mechanism, and I treat them all basically the same way. Just as with the foot, the hand is the end of the line, so to speak, of adaptation for problems originating higher up in the arm – and almost always originally beginning in the lower body. Because these problems are symptoms of problems elsewhere that are not being addressed, surgical solutions remove the body's preferred adaption and require it to find a different one. Cutting the retinaculum, the tendon holding the wrist together, will certainly relieve carpal tunnel pain by creating more space for the nerve; but it also allows the little bones of the wrist to move around more, because now there is less restriction on them.

Many similar problems occur in the hand as in the foot: nerve pain, ganglion cysts, frozen digits, swellings, and bumps, all problems that I think we can correct by working on the ligaments. Because I see the upper body as being related to the lower body, I see that we have to fix the lower body as well as the upper body, if we intend to make any permanent reversal of symptoms.

## 8. Head

### Figure 8a: Thoracolumbar Fascia

*Showing some of the muscles and tendons originating there and stretching in all directions.*



The thoracolumbar fascia (Figure 8a) is a large, triple-layer structure “that functions in a manner similar to a ligament in the lumbar area” (Mosby's Medical Dictionary, 8th edition. Elsevier, 2009). It attaches to many things, including the pelvis and sacrum, parts of the vertebrae and ribs, and ligaments in the pelvis and the neck. It is the origin of the abdominal muscles as well as fibers of the latissimus dorsi, and muscles like the erector spinae and quadratus lumborum are situated between its layers. The thoracolumbar fascia unifies and integrates the motion of the upper body, including the head, with the motion of the pelvis.

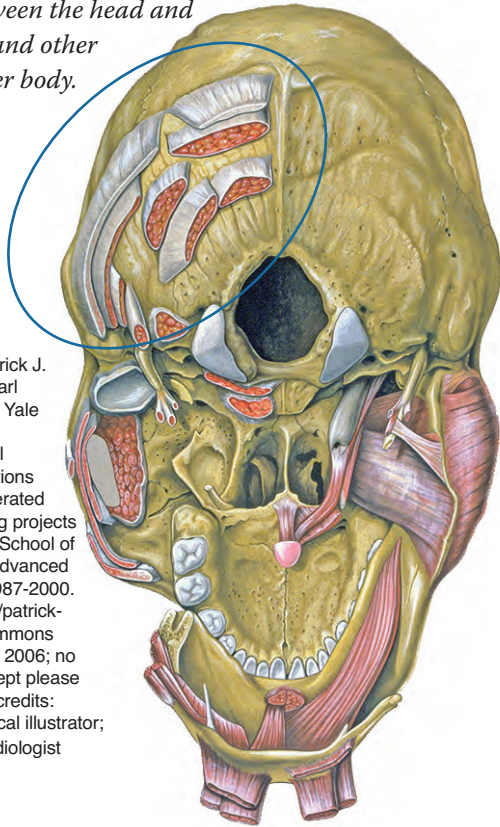
Like everywhere else in the body, the head has mechanisms that keep it from pulling or falling off. Torsions in the pelvic girdle are counterbalanced by torsions in the shoulder girdle and skull. These torsions are often described as scoliosis because we tend to focus on the curvatures that these torsions create in the spine rather than on the torsions themselves. Restrictions in the pelvic girdle that prevent it from returning to a neutral position are what create curvatures, or twists, in the spine. Because the vertebrae are coupled, their movement and position are not independent of one another. A curve to the right in the lumbar must be counterbalanced by a curve to the left in the thoracics, just as an outflare of the right pelvis must be counterbalanced by an inflare of the left pelvis, if we are to maintain balance without using assistive devices such as canes and walkers.

As we get to the end of the line moving up the spine, we see a slightly different mechanism than we saw in the extremities. In the extremities, the distal ends contain many small bones that can move to accommodate the restrictions coming from more proximal joints. As we move up the spine, we can see the column of vertebrae changing its position to accommodate the restrictions below, but the spine is a stack of bones, not a fan of bones like the hands or feet. What happens at the top of the stack is quite interesting. Imagine that the spine is an articulated set of blocks with a bowling ball resting on top. The bowling ball is attached in such a way that it can change its position as needed so that it does not fall off the stack of blocks as the stack twists, bends, and moves through space. The head can make minute and precise adjustments to counterbalance what is happening in the spine and the girdles because of the multitude of small muscles, tendons, and ligaments securing the neck and the head, both on the outside of the skull (Figure 8b) and inside and around the spinal column (Figure 8c).

*(continued on the next page)*

**Figure 8b: Muscle Attachments at Base of Skull**

*Muscles have been cut away to show the multitude of connections between the head and neck, and head and other parts of the upper body.*

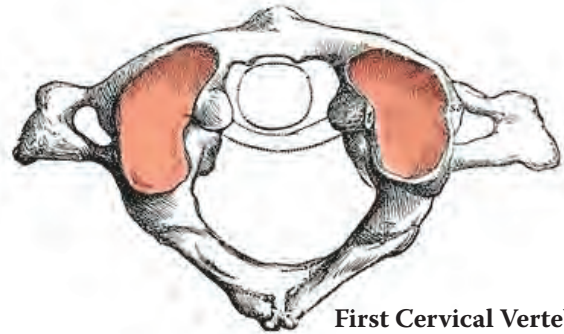


Attribution Details: Patrick J. Lynch; illustrator; C. Carl Jaffe, MD; cardiologist Yale University Center for Advanced Instructional Media Medical Illustrations by Patrick Lynch, generated for multimedia teaching projects by the Yale University School of Medicine, Center for Advanced Instructional Media, 1987-2000. Patrick J. Lynch, <http://patrick-lynch.net> Creative Commons Attribution 2.5 License 2006; no usage restrictions except please preserve our creative credits: Patrick J. Lynch, medical illustrator; C. Carl Jaffe, MD, cardiologist

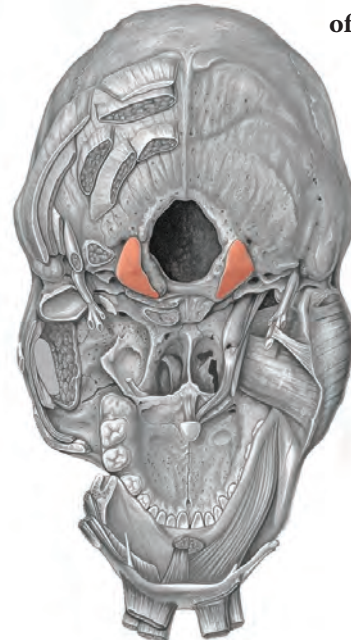
In addition, the neck and head are connected by two synovial joints, the atlanto-occipital joints, one on either side of the spinal column (Figure 8c and Figure 8d). These joints are different from the other joints we have discussed because they are condylar joints. One surface is ovoid and fits into an elliptical cavity on the other bone. This allows movement in two planes, but no rotation. The skull, then, can tilt in various directions to balance the forces from below, but all rotating is done by the cervical spine. As with the planar joints, when the atlanto-occipital joint reaches the limit of its range of motion, it tends to get stuck there, preventing damage to the blood vessels and nerves that pass through the skull to the brain.

**Figure 8d: Atlanto-Occipital joint**

*Upper: Superior surface of C1 vertebra, showing surface that articulates with occiput. Lower: Inferior surface of skull, showing surface of occiput that articulates with C1 vertebra.*



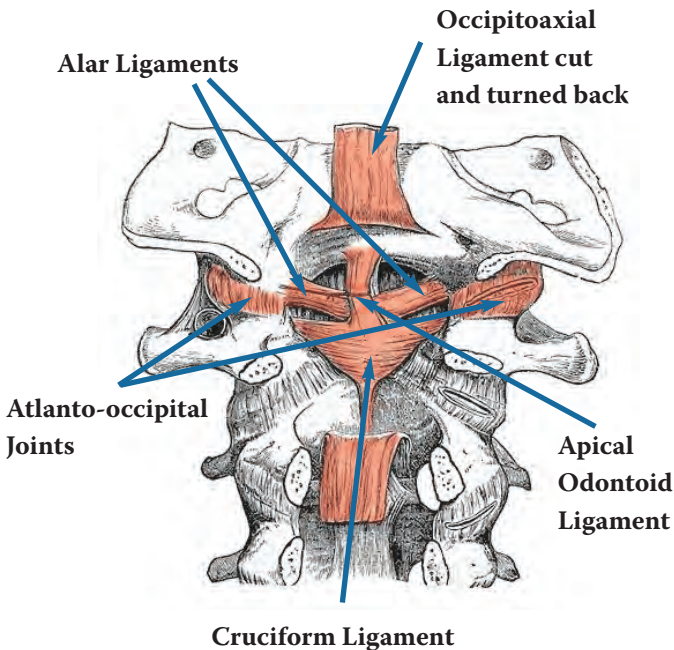
First Cervical Vertebra (C1), showing Elliptical Cavities of Superior Facet



Underside of Occiput, showing condyles that articulate with Elliptical Cavities in the C1 Superior Facet

**Figure 8c: Ligaments Between Skull and Neck**

*Some of the ligament attachments connecting the base of the skull and the neck on the inside and the outside of the spinal column.*



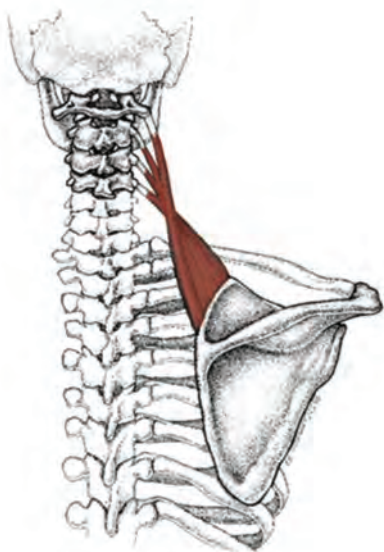
The neck and head have many connections to the shoulder girdle. These connections convey any torsion



in the shoulder girdle directly to the neck and skull. For example, the levator scapula originates on the scapula and inserts on the upper four cervical vertebrae (Figure 8e). If the scapula is always rotated because it is being pulled by a pelvic torsion, then the neck is always going to be rotated as well, and the head is going to adjust its position to counterbalance this rotation.

### Figure 8e: Levator Scapula

*Illustrating one of the connections between the shoulder girdle and the neck.*



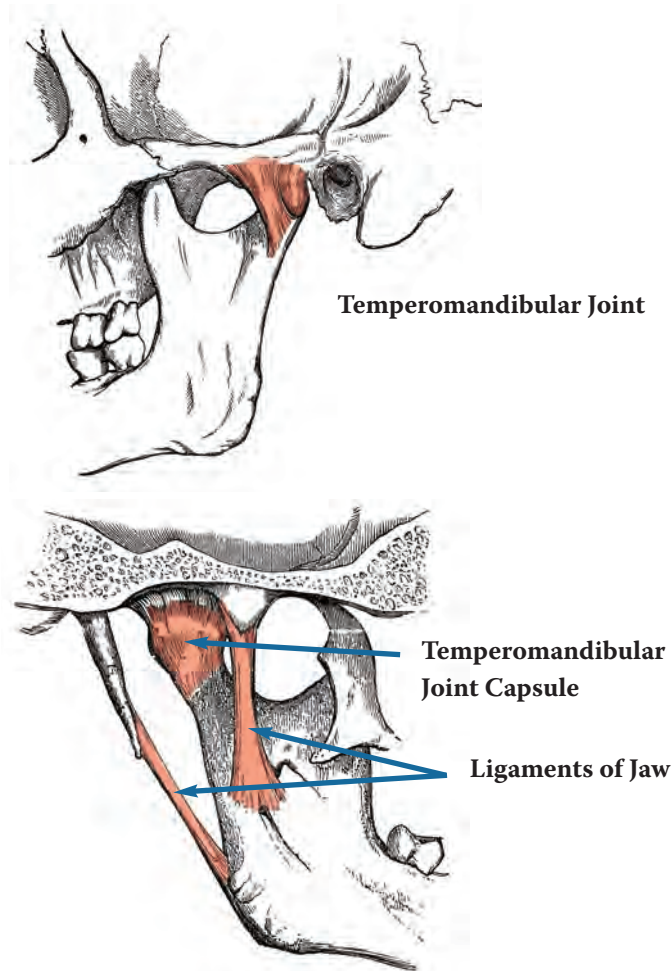
The constant pull on the skull from torsions in the pelvic and shoulder girdles actually changes the shape of the head. I realize this is a controversial statement. Many people believe that the bones of the head are fused and do not change their shape. However, those of us who are able to release the pressures on the skull have seen and felt with our fingers sometimes dramatic and sudden changes in the shape of the skull, demonstrating just how adaptable the skull can be. As I mentioned in the sidebar at the beginning of this article, my own face was realigned by an osteopath who gently moved the bones of my face with his fingers.

I believe these torsions in the skull and the accompanying pressures and restrictions in the cervical vertebrae are the main reason we see so many people with problems such as headaches, tinnitus, and hearing loss. I treat all of these problems by releasing the pressures in the neck and head and restoring their alignment. Obviously, this is not the cause for everyone, and it is not possible to restore hearing, balance, or peace and quiet when the problems have persisted so long that nerves are damaged; but I have seen people recover who were not expected to improve.

## 9. Jaw

### Figure 9a: Temporomandibular Joint

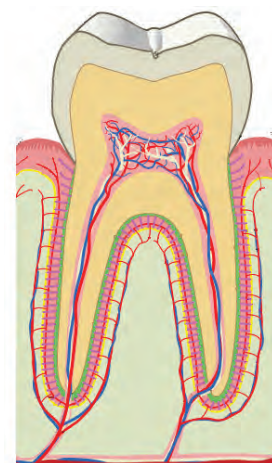*Upper: Ligaments attaching the lower jaw to the skull, as seen from the outer surface of the mandible. Lower: Ligaments attaching the lower jaw to the skull, as seen from the inner surface of the mandible. The entire lower jaw hangs by these two sets of ligaments, so is able to adapt to many positions of the skull.*



### Figure 9b: Periodontal Ligament Surrounding the Roots of the Teeth

*The ligament allows the tooth to move in the jaw.*

Skull torsion has a direct effect on the jaw, where we find the end of the line for adaptation moving up the spine and into the head – the teeth. The jaw hangs from the skull by two small joints, the



*(continued on the next page)*

temperomandibular joints (Figure 9a). Torsion in the skull will change the way the jaw hangs and the way the teeth meet in the mouth. Like every other bone in the body that articulates with another bone, teeth are held in the jaw by ligaments (Figure 9b); and just like every other joint in the body, the teeth in the jaw can change their alignment to accommodate the pressures being placed upon them. This is why people have bite problems, why teeth crack and break, and why teeth shift position. This is also why some corrections of teeth alignment with braces appear to fail after the braces are removed. When torsions persist below, they will be reflected in the teeth. The teeth are the end of the line of adaptability. Pressures coming from below, from the pelvis and lower extremities, are transferred to the jaw via the shoulder girdle and the spine and skull. For this reason, teeth, especially bite problems, should not be treated in isolation from what else is happening in the body. The body is constantly seeking equilibrium. Joint alignment is a continual adaptive process.

## Treatment Implications

Structure predicts function and informs diagnosis and treatment. The body is an incredibly dynamic, adaptable, and integrated construction. It is designed to function within a large range of possible joint alignments. You can see this for yourself by flexing and extending your elbow. You can flex it in every position from extreme pronation to extreme supination. When a contracted or injured ligament restricts motion in a particular joint, the rest of the body accommodates to the problem. Most of the time we do not even notice, until the accommodation reaches an endpoint somewhere, perhaps created by injury elsewhere or simply by reaching the “end of the line” of adaptation. How the body will accommodate is predictable and follows the pathway of least resistance. This is what I have traced in this article. Because the body is adaptable and the pathway is predictable, it is also reversible. How far we can retrace the pathway to completely neutral, unrestricted function is determined by what kinds of injuries we have had, how long we have had them, how much “collateral damage” has occurred from wear and tear while using restricted joints, and what kinds of treatment we have had. How rapidly we can retrace the pathway is determined by age, diet, general health, activity level, medications, and similar considerations.

Current medical practice involves well-developed treatment strategies for affecting muscles and for replacing

severely damaged joints. It is my contention that muscle treatments address only a portion of what is involved in orthopedic problems, and joint replacement is only an option when no other treatment is possible. We need to treat all the layers – the energetic pathways (meridians), the soft tissue (muscles), the stiff tissue (tendons, ligaments, and fascia), and the hard tissue (bones). This is why it is so important for the various health professions to work together. We all contribute a piece to treatment.

The weakest link in a combined treatment strategy is the treatment of the stiff tissues, largely because we do not think about them, or, if we do, we address them piecemeal, as individual joints, or layer by layer, rather than as an integrated system. For example, chiropractic tends to focus on spinal adjustments but typically does not follow up by aligning the joints of the lower and upper extremities in the same session. As another example, myofascial massage tends to focus on releasing restrictions in the fascia that sheaths our bodies beneath the skin but typically does not follow up by aligning joints. This does not have to be the case. It is possible to treat all the layers using only manual therapies.

Acupuncturists, too, tend to focus on only a piece of a combined treatment strategy, typically the energetic pathways and selected *ashi* and/or motor points in the muscles. Acupuncture is an extremely versatile treatment system. Needles can be directed in different ways to accomplish different things; and Oriental Medicine includes all the elements that should be included in a combined treatment strategy, with the exception of surgery, which we hope to need only when all else has failed or when the problem is so out of the ordinary that surgery is the only option.

Needling stiff tissue requires a different technique from needling the regular acupuncture points (meridian points or *ashi* points). The technique is similar to that used for needling motor and *ashi* points; but the best needle is a heavier gauge, and the stimulation is stronger. My preferred needle is *Seirin* #8 (0.30), which is now available in 30, 40, 50, and 60 mm lengths. *Tai Qi* makes a 0.50 gauge needle in 75 mm length which I also sometimes use with an improvised pipette; the one provided with the needle is too long and does not allow you to achieve any depth of insertion. Most ligaments are surprisingly close to the surface of the body and can be accessed with 30-60 mm length needles on most people, including many clinically obese people.

## Tendon Lotion

Chinese	Pinyin	Amount
草烏	Cao Wu	4 qian (12 grams)
川烏	Chuan Wu	4 qian (12 grams)
桃仁	Tao Ren	4 qian (12 grams)
麻黃	Ma Huang	4 qian (12 grams)
乳香	Ru Xiang	4 qian (12 grams)
沒藥	Mo Yao	4 qian (12 grams)
自然銅	Zi Ran Tong	4 qian (12 grams)
大黃	Da Huang	4 qian (12 grams)
路路通	Lu Lu Tong	4 qian (12 grams)
樟木	Zhang Mu	4 qian (12 grams)
馬前子	Ma Qian Zi	4 qian (12 grams)
天南星	Tian Nan Xing (raw)	4 qian (12 grams)

**Note:** The last two ingredients are toxic and are sometimes left out. The formula works well without them.

### How To Apply Tendon Lotion

Put a small amount of Tendon Lotion on the ball of your thumb or on the pads of two or three fingers. Massage the liniment gently into the injured area. Pressure should be deep enough to penetrate, but not so deep as to be painful. Make small circles with your thumb or fingers to work the liniment into the injured tissues. Continue to rub the liniment into the area for several minutes, adding more to your fingers as needed. For an injury like shin splints, where small microtears in the muscle are pulling the muscle away from the bone, massage in circles gently toward the bone, using Tendon Lotion. ♦

Reprinted with permission from Tom Bisio.

### Reference

Bisio, Tom. *A Tooth from the Tiger's Mouth*. NY: Simon and Schuster, 2004.

A typical treatment would proceed in this manner:

#### 1. Prepare the tissues

- Apply a liniment intended for treating tendons and ligaments, such as Tom Bisio's Tendon Lotion, or Dit Dat Jiao.
- If tissues are very tight, also apply a warming oil or salve, such as Po Sum On oil, Shiling oil, and/or Amber Massage Salve, and massage the tissues to soften them, or use a *gua sha* technique that will not bruise the skin or discolor it.

#### 2. Acupuncture

- Begin with needles placed in tendons and ligaments and retain them until the tissues have softened.
- Meridian acupuncture and retained needles in motor points can be done simultaneously.
- Apply an anti-inflammatory, analgesic, and circulating formula around the needles, such as Zheng Gu Shi, along with a warming liniment or oil, such as Shiling oil, if you have not already done so.
- Apply light, indirect moxa around the needles. If you make the tissues too warm, you will not be able to manipulate them with the needle.
- When the needles loosen, test their depth to make sure that all the layers of tissue have softened.
  - If the needles are loose, remove them.
  - If there is still tension in the tissues, either retain the needle a while longer, or tug on the needle to obtain a twitch. Tissues that are too warm will not twitch.

#### 3. Manual Therapy (the entire treatment can be done manually, without acupuncture)

- The liniment and oils used in Step 1 should be sufficient lubrication. Be careful not to use too much lubrication, or you will not get sufficient traction to reach the deeper layers.
- Use myofascial techniques to release fascia and tendons. Pinning and stretching is very effective.
- Bones are very effective massage "tools" for releasing ligaments so that the joints can be realigned.

#### 4. Concluding the treatment

- "Clean up" areas that have not released completely. Use a "peck and stretch" technique with acupuncture needles, or "pin and stretch" if using all manual techniques.
- Realign the joints, using the bones as "massage tools" to release the ligaments.
- Calm the tissues by applying an anti-inflammatory analgesic, such as an emu oil formula (e.g., Re'leve), Sombra, or China Gel.

(continued on the next page)

## 5. Home Care

- a. Topical preparations can be chosen according to the patient's needs to be used at home for self care.
- b. Qi Gong, Tai Qi, and some types of yoga or Pilates exercises can be very helpful for maintaining the treatment and strengthening the tissues in their new alignment.
- c. General exercises which allow the body to twist and turn as needed, such as cycling, walking, and swimming, are usually very helpful. Avoid intense closed-chain exercises.
- d. Anti-inflammatory diet can be very helpful, especially one that is low in refined sugar (which is a pro-inflammatory agent) and high in dark green leafy vegetables (which are high in nitric oxide, which is necessary for proper blood circulation, especially after middle age).
- e. Herb formulas can be selected according to the patient's needs.

The twitch response is a desirable outcome from needling or manual work. Detailed instructions for this style of needling in the thoracic and lumbar spine are given in an earlier article published in OMJ (Rogel, 2007). A similar technique can be used at other joints, though I do not attempt to obtain a twitch when needling the extremities. I prefer to obtain the twitch with manual methods in the extremities and often do minimal needling there. Unfortunately, detailed information about needling the individual Keys is beyond the scope of this article.

The twitch represents the resetting of contracted tissue to its relaxed state, which then creates space that will enable the practitioner to realign a joint that has become "stuck" at one end of its range. When the joint is realigned, the patient generally experiences immediate pain relief and increased range of motion. The tissues may need several days or even a couple weeks to recover from the treatment. When the joint has been compromised in its motion for a long time, many changes occur, including wear on the cartilage and shortening of muscles. The body needs time to remodel the inside of the joint and to grow new tissue inside and outside the joint, as well as to strengthen muscles and stiff tissue that has had to function in an alignment that was less than optimal. Think about the changes that need to happen when a joint is replaced. Everything in the body has to find a new alignment. This same thing happens as a consequence of the comprehensive treatment I have described, but on a smaller scale.

How much I am able to accomplish in a treatment session depends on the patient's presenting complaint, overall health

picture, response to treatment, and where we are in the treatment sequence. At the beginning, I may have to proceed slowly and perhaps will only be able to treat the Foundation. Later, I will be able to treat the entire body in one session. Toward the end of treatment, I sometimes need to allow more time between sessions so that the changes can settle in. For acute injuries, especially for young people, I may be able to resolve the patient's problem in one session. People with chronic problems, especially older people with multiple issues, often prefer to come for regular treatments for years. Many of my patients credit this style of treatment with keeping them active and relatively pain-free well into their 80s and 90s.

## Conclusion

If I had to use one phrase to summarize how the body responds to injury, it would be this: Every part of the body is continually seeking equilibrium. I think of joints, in some ways, like a fisherman's net. If you lay out the net and pick up one of the knots, all the knots will move with it. I am saying the same thing about how the joints of the body work. If one of the sacroiliac joints does not move properly, it is going to have an effect on every joint in the body in the same way that picking up the knot in the fisherman's net moves all the knots.

I would like to propose that ligaments are the most important factor in understanding, diagnosing, and treating orthopedic problems. Ligaments hold bones together; they are strong enough to keep us from falling apart and flexible enough to enable our joints to articulate in many different positions or alignments. We pay much more attention to muscles and try to treat orthopedic problems by treating muscles. Indeed, we even have an alternative word for describing orthopedic problems, "musculoskeletal," which shows where we put our diagnostic and treatment attention. However, in my opinion, the muscles literally go along for the ride. The muscles are attached to the bones; muscles go where the bones to which they are attached go, and the bones go where the ligaments allow.

The treatment strategies that I would like to encourage are treatments that look at the body as a whole and that preserve the ability of the body to continue adapting, because it is going to adapt, no matter what we do. Once wear and tear begins to occur in the joints, it is going to continue in that direction because of the pressures and mechanisms that I have just outlined. The body cannot reverse wear and tear by itself. We have to do something to reverse it. If we do not reverse it, the cascade will continue moving in the direction it is going until something stops it. For example, when the foot cannot adapt any more and the arch has become flattened,

the adaptation in that direction has stopped itself. That does not necessarily mean that the problem will stop, but it will not progress any further in that direction. Likewise, once a hole is worn in the hip socket, the femur becomes locked in the joint and the deterioration will not progress further in that direction. You may not be able to walk very well, but you are not going to have much more damage occurring inside that joint unless you try to force it to move.

Regardless of the type of medicine we practice, we have a tendency to work in a fragmented way. The style of thinking that is held up as the ideal is what we call reductionist rather than holistic. Unfortunately, holism has become faddish; many practitioners call themselves holistic, but few really understand what it means to think holistically. Conceptually, we divide the body into parts, and then we talk about the parts as though they are not related to each other. We focus on what the parts are doing rather than on what the whole is doing. We may sing about the hip bone being connected to the thigh bone, but we really do not understand the implications of that connectedness.

Most of us were raised in a culture that is organized under the reductionist paradigm; and, except for our professional OM education, we were educated in schools that teach only reductionism. Holism is a fairly new concept even for most of us, and it is easy to be pulled back into reductionist thinking

patterns, especially when our medicine is being attacked as not being “evidence based,” as judged by reductionist thinkers, and when we are trying to prove the worth of our medicine by applying the “gold standard” of reductionist thinking, the random control study.

As a culture, we hobble our health care providers because we assign different professions to work on different parts of the body, and we define which professions can use which treatment methods. We limit our ability to learn from each other, and we limit our ability to treat people effectively. Yet we are all working on the same body! It is inevitable that we are going to discover each other’s techniques. By working together across disciplines and with our patients, I believe it is possible to find solutions to orthopedic problems that preserve as much as possible of the joints’ adaptive functions.

I believe that we can find treatment solutions that will pull our patients back from the brink, so to speak. I believe it is possible to slow down, and maybe even stop, the wear and tear process by shifting our main emphasis from muscle-based therapies to ligament-based therapies, by realigning joints in a holistic manner, and by tailoring therapies to the particular needs of individual people. Health care professionals need to work together to treat all the different depths of the body. The cascade I described is predictable. Once we understand it, we can travel the path in either direction. ♦

## References

Dislocated shoulder. [https://en.wikipedia.org/wiki/Dislocated\\_shoulder](https://en.wikipedia.org/wiki/Dislocated_shoulder), downloaded 07 September 2015.

Rogel, M. J. An alternative explanation for Peripheral Artery Disease. *AZSOMA Newsletter*, Spring 2011, pp 6-9.

Rogel, M. J. Building on bedrock: Rethinking Orthopedics. *Oriental Medicine Journal*, Fall (Metal), 2010.

Rogel, M. J. Introducing “Gold Needle” acupuncture: The lamina points, the facet points, and a method for needling them. *Oriental Medicine Journal*, Fall (Metal), 2007, pp. 14-23.